

## THE STUDY OF OUTCOME OF MITROFANOFF PROCEDURE IN URINARY TRACT RECONSTRUCTION

Immadi Chandrasekhar<sup>1</sup>, A. V. Mohana Rao<sup>2</sup>

### HOW TO CITE THIS ARTICLE:

Immadi Chandrasekhar, A. V. Mohana Rao. "The Study of Outcome of Mitrofanoff Procedure in Urinary Tract Reconstruction". Journal of Evolution of Medical and Dental Sciences 2015; Vol. 4, Issue 35, April 30; Page: 6027-6034, DOI: 10.14260/jemds/2015/878

**ABSTRACT: BACKGROUND:** In 1980, Dr. Paul Mitrofanoff described a procedure using the appendix to construct a continent catheterizable channel to the bladder. This concept has come to be known as Mitrofanoff procedure. Aim is to evaluate the outcome of Mitrofanoff procedure. **SETTINGS AND DESIGN:** This is a one centre prospective study done in King George Hospital, Andhra Medical College, Visakhapatnam from August 2005 to December 2014. **PATIENTS AND MATERIAL:** Mitrofanoff procedure is performed in 15 patients between August 2005 to December 2014. **RESULTS:** Subcutaneous wound infection occurred in 4 cases, stomal stenosis in 3 cases, and difficulty in catheterizing channel in 3 cases which were rectified. Occasional cystitis is seen in all the 15 cases. All the 15 patients are doing clean intermittent catheterization without any problems until last follow-up. **CONCLUSIONS:** Mitrofanoff's procedure enjoys the single feature of affording a catheterizable continent diversion using appendix that can be performed utilizing techniques already in the urological armamentarium. Long term complications are less with this procedure.

**KEYWORDS:** Appendix, Clean intermittent catheterization, obstructed labour injury complex, road traffic accidents, stoma, suprapubic cystostomy, urethral strictures.

**MESH TERMS:** Adult, Appendix/surgery, Female, Humans, Male, and Postoperative care, Post-operative complications, Treatment outcome:

- Urinary Bladder, Neurogenic/surgery.
- Urinary Reservoirs, Continent/adverse effects.
- Urinary Reservoirs, Continent/methods.
- Urological Diseases/surgery.

**INTRODUCTION:** In Mitrofanoff procedure, appendix is used to construct a continent catheterizable channel to the bladder.<sup>[1]</sup> Although it was originally described for use in children with neurogenic bladders, it is being widely used for many clinical situations. Channel continence is maintained by creating a flap valve by tunneling the channel into the bladder using techniques similar to ureteric reimplantation. Surgical experience with Mitrofanoff's principle has increased over the years with high patient satisfaction. It has become an extremely important adjunctive technique in urological reconstruction. Further experience with the procedure and onset of complications instigated the description of various stomal options and conduit implantation techniques. Most recently, laparoscopic and robotically assisted techniques have also been performed.<sup>[2]</sup>

**PATIENTS AND METHODS:** Mitrofanoff's procedure is performed in 15 patients between August 2005 to December 2014 at King George Hospital, Andhra Medical College, Visakhapatnam.

Out of 15 patients, 12 are stricture crippled with failed recurrent irreparable urethral stricture after traumatic posterior urethral injuries. 3 are female patients with obstructed labour

## ORIGINAL ARTICLE

---

injury complex with bladder neck contracture and urethral loss. All the 15 patients are on permanent SPC, and would remain on SPC if the Mitrofanoff procedure is not performed.

**Procedure of Mitrofanoff Operation:** A lower midline incision that is carried around the umbilicus to leave enough fascia to close the abdomen without compromising an umbilical stoma, is given. A lower transverse incision can also be given in thin patients.

**Mobilization of Appendix:** The appendix is verified for the presence of any inflammation. If there is any significant inflammation, appendico-vesicostomy is deferred and alternative procedure like Yang- Monti ileovesicostomy can be planned? In Mitrofanoff procedure, the right colon is mobilized beyond the hepatic flexure to allow maximal freedom of the appendiceal mesentery.

**Mobilization of Bladder and Cystotomy:** Prior to detaching the appendix, the bladder is mobilized to ensure that the bladder and appendix can easily reach the chosen site for the abdominal stoma without tension. The bladder is then opened to the left of the midline for a right lower quadrant appendico-vesicostomy or in a wide U-shaped anterior bladder incision for an umbilical stoma.

**Detaching the Appendix:** The appendix is detached from the caecum either sharply or with a stapling device, and the caecum is closed. The mesentery with appendiceal artery can be freed from the caecal mesentery to allow complete mobilization of the appendix if needed. The terminal end of the appendix is then opened, and a 12 french catheter is passed to ensure that the appendix has an adequate lumen.

**Bladder Hiatus:** The site of the bladder hiatus is then selected, again ensuring that it can easily reach the anterior abdominal wall without tension. The site of hiatus is opened wide enough to allow the appendix to pass without any tension.

**Creation of Sub Mucosal Tunnel:** A sub mucosal bladder tunnel is then created from the hiatus using sharp dissection. The tunnel length should be at least 2.5 cm. The terminal end of the appendix is then passed through the bladder hiatus and sub mucosal tunnel. The appendix is then spatulated and secured distally with two 4-0 absorbable sutures incorporating full thickness bites of the appendix and detrusor muscle and mucosa. The remainder of the anastomosis is completed using 4-0 or 5-0 absorbable sutures, securing the bladder mucosa to the appendix. The channel is catheterized with a 12 or 14 Fr catheter to ensure that it passes easily across the hiatus and sub mucosal tunnel.

**Construction of Stoma:** A U-shaped or a V- shaped skin incision is made at proposed stomal site and the flap is freed sharply to the level of the fascia. A cruciate incision is made in the fascia and widened to allow passage of an index finger. The appendix is then brought through the fascial opening and the bladder hiatus is secured to the fascial wall using 3-0 absorbable sutures, taking care not to angulate or compress the appendiceal mesentery. The caecal end of the appendix is then spatulated on the antimesenteric side. The stomal anastomosis is secured using interrupted 4-0 absorbable sutures. The stoma is then catheterized multiple times with the bladder both distended and empty to ensure that there is no angulation in the channel. A 12 Fr catheter is left indwelling for 3 weeks before initiating intermittent catheterization.

## ORIGINAL ARTICLE

---

### **Few cases are discussed here:**

**Case 1:** A 56 year old male patient had a road traffic accident with fracture of pubic bones and retention of urine with urethral injury, for which SPC was done in 2003. Four months after the initial injury, when the patient was ambulant, end to end urethroplasty with inferior pubectomy was done. Perurethral foley's catheter was removed after 3 weeks. The patient voided urine for 2 weeks and stream was narrowed. Urethral cystoscopy and VIU were done after 6 weeks. The patient again developed narrowing of urinary stream after one year and cystourethroscopy was done, which revealed dense stricture at the anastomotic site. Internal urethrotomy was done. The patient came in retention of urine after 3 months, for which SPC was done. Tran's pubic urethroplasty was done. The patient could not pass urine after catheter removal. The patient was counselled about Mitrofanoff's procedure and permanent SPC. The patient opted for Mitrofanoff's procedure. Routine blood investigations were normal. Mitrofanoff procedure was performed. No. 10 Fr feeding tube was kept as urethral stent. SPC was kept. After 2 weeks, the stent was removed and the patient was taught about CIC. SPC was removed when the patient was confident of CIC.

**Case 2:** A 23 year old female patient came to the labour room with acute retention of urine immediately following caesarean section at a private hospital for obstructed labour of 24 hr at her residence. Per abdominal examination: Bladder is distended upto umbilicus, sutured lower midline incision is present. Vaginal examination revealed oedematous and inflamed vaginal walls, lacerated wound in the anterior vaginal wall and urethral meatus is erythematous. Perurethral catheterization was attempted, but catheter was coming out through a laceration in posterior urethral wall into the vagina just 0.5 cm proximal to the urethral meatus. Proximal urethra could not be traced out. Trocar SPC was done. After 3 months, cystourethroscopy was attempted. Scope could not be negotiated 1 cm beyond the meatus. Urethra was blind ending. Antegrade cystoscopy revealed closed bladder neck. Ureteric orifices and rest of the bladder was normal. The patient was counselled about Mitrofanoff procedure and permanent SPC. The patient opted for Mitrofanoff procedure. Mitrofanoff procedure was performed. No. 10 Fr. feeding tube was kept as a stent. SPC was kept. A CRD was kept in the Retzius space. Drain was removed on the third POD. Sutures were removed on the eighth POD. The stent was removed after 2 weeks. The patient was taught about CIC. SPC was removed when the patient was confident of CIC. In the follow-up patient is continent and is comfortable with CIC.

**Ethics:** We have taken the written consent of the patients to be enrolled in the study and to publish the photographs also.

**RESULTS:** 40 %( 6) of the cases are in the age group 20 to 30 years. 13.33 %( 2) are in the age group 30 to 40 years, 26.66% in 40 to 50 age group and 20% are more than 50 years.

Of the 15 cases, 12 (80%) are male patients and 3 (20%) are female patients.

Mitrofanoff procedure is done in cases where urethroplasty has failed in 12 (80%) cases and in obstructed labour injury complex in 3 (20%) cases.

Subcutaneous wound infection occurred in 4 (26.66%) cases, which were treated with antibiotics and drainage. Stomal stenosis occurred in 3 (20%) cases where revision of the stoma with well vascularised flap of skin is done. Difficulty in catheterizing channel occurred in 3 (20%) cases. Catheter dilatation is done. Occasional cystitis is seen almost all the cases which were treated with antibiotics. The overall success rate is 100%. All the 15 patients have continent catheterizable channel.

## ORIGINAL ARTICLE

---

**DISCUSSION:** The 12 stricture cripples underwent surgeries twice or more with recurrent irreparable strictures due to lengthy defects and previous infections with sinuses in the perineum. The 3 female patients had bladder neck contracture and total urethral loss following prolonged obstructive labour. One patient delivered normally and went into retention of urine in the immediate postpartum period. The other two patients underwent Caesarean section and were in retention of urine in the immediate post-operative period. For these three patients SPC was done immediately. At the time of Mitrofanoff's procedure, all the patients were on SPC.

These 15 patients are intelligent enough to participate in the post-operative self-catheterization programme, as the success of this procedure depends on clean intermittent catheterization. The Mitrofanoff procedure has been found to improve the lives of people with spinal cord injuries also, by increasing their independence.<sup>[3]</sup>

Appendix is used as a conduit in all the patients and the appendix is of sufficient calibre and long enough to perform appendicovesicostomy. Even though umbilical stoma appears to be cosmetically good, we selected right lower quadrant to construct stoma because it is technically less demanding. It is easy to bring the appendix to the right lower quadrant of the abdomen.

Preoperatively bowel is prepared by both antibiotic and mechanical bowel preparation. Stomal site is selected preoperatively with the patient both standing and supine positions.

We can use other structures like ileum and caecum as continent catheterizable channels.<sup>[4]</sup>

**Complications:** Potential complications of Mitrofanoff's procedure include stomal stenosis, stomal incontinence, difficulty in catheterizing channel, intra-abdominal adhesions, painful catheterization, prolapsed stomal mucosa, peristomal hernia, wound dehiscence/infection.

The most common complication is stomal stenosis, occurring in 10 to 20% of channels in most series. The continent vesicostomy has a much higher rate of stenosis than either appendix or Monti- Yang channels. A short period of catheter dilation will avoid the need for surgical intervention in some patients. If necessary, revision of the stoma with a well vascularised flap of skin is usually successful to manage significant stenosis.

Difficulty in catheterizing the channel can occur secondary to angulation, perforation or false passage or stenosis of the channel. Initially this should be treated conservatively with placement of an indwelling catheter for 1 to 2 weeks. In some occasions, reoperation will be necessary, and the patient and surgeon should be prepared to replace the entire tube if required.

In a study by Suzer O and Vates TS et al,<sup>[5]</sup> stomal continence was achieved in 42 of 43 patients (98%), difficulty in catheterization occurred in 32%, stomal prolapsed in 2%. In our study, stomal continence was achieved in 100% of cases and difficulty in catheterization was observed in 20% of cases. In another study by Fishwick JE and Gough DC et al,<sup>[6]</sup> all the nine patients had their original stoma and all were completely continent, four of the patients had stenosis, four had stones and four had been ill with urinary tract infection. In our study, 3 (20%) out of 15 patients had stomal stenosis. None of our patients developed stones.

Liard A and Mitrofanoff P et al,<sup>[7]</sup> in their study, followed their patients for more than 15 years. 23 continent cystostomies were done with neuropathic bladders. But in our study, we have done Mitrofanoff procedure for failed urethroplasty due to road traffic accidents and obstructed labour injury complex. In the study by Liard, stomal stenosis and persistent leak occurred in 11 cases, which required surgical revision. There were no complications of persistent leak in our study.

## ORIGINAL ARTICLE

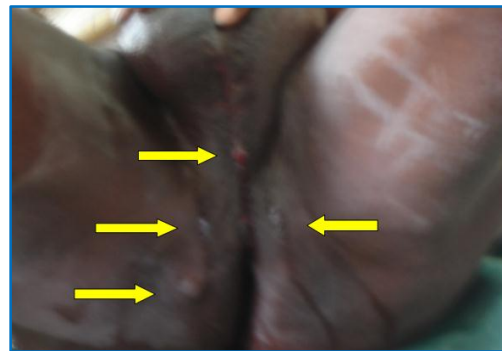
According to the study by Clark and Pope JC et al, 65 stomal procedures were performed in 47 patients using various structures like appendix, bladder tube, Yang- Monti tube, ureter, etc. The choice of tissue for constructing the continent catheterizable channel is not as important as patient compliance, age and possibly body habitus according to Clark et al.<sup>[8]</sup>

Complications can occur many years after construction of a Mitrofanoff channel, and long term follow-up with these patients is mandatory, especially when the Mitrofanoff channel is the sole means to empty the bladder. We ask the patients to come every month for first 3 months, every 3 months for first one year and every 6 months thereafter for follow-up or when they encounter any complication.

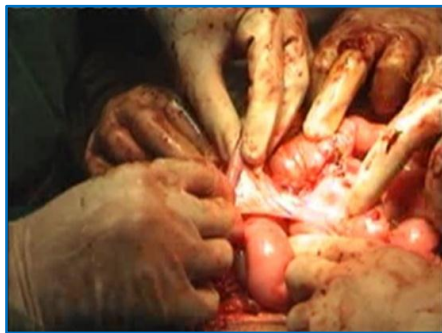**CONCLUSIONS:** Mitrofanoff procedure enjoys the single feature of affording a catheterizable continent diversion using appendix that can be performed utilizing techniques already in the urological armamentarium. Appendicovesicostomy can be performed relatively easily and is less time taking. The patients can get rid of permanent SPC and can lead near normal life. To achieve satisfactory results, careful patient selection is essential. It is desirable to have highly motivated patient with realistic expectations and normal intelligence, who are physically and emotionally capable of dealing with strict regimen of CIC so as not to jeopardize the entire procedure. This study reinforces the importance of careful screening and vigorous preoperative and postoperative teaching to achieve overall patient success.



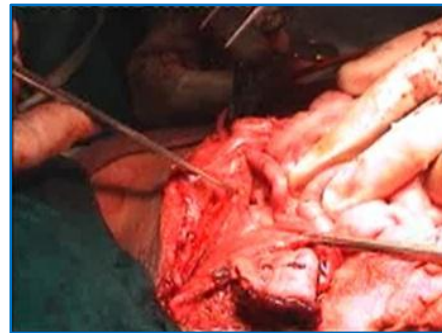
**Fig. 1: Patient with obstructed labour injury complex**



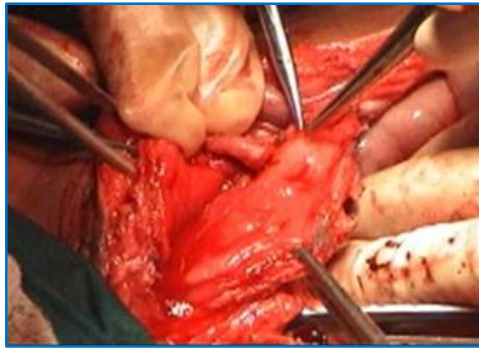
**Fig. 2: Patient with multiple perineal sinuses after failed urethroplasty**



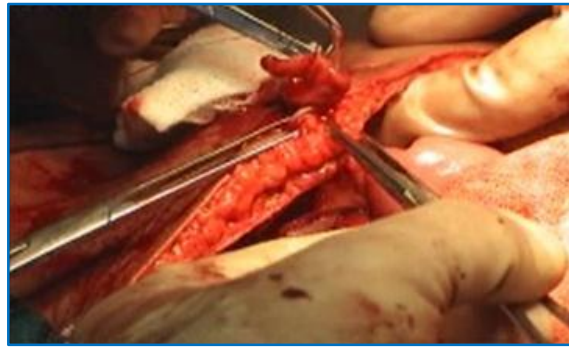**Fig. 3: Mobilization of appendix along with mesoappendix**



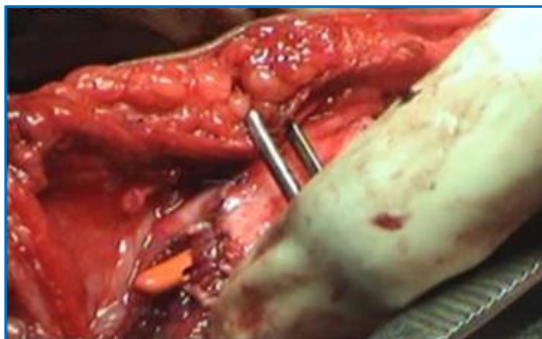**Fig. 4: Fixing the bladder to anterior abdominal wall and making bladder hiatus**



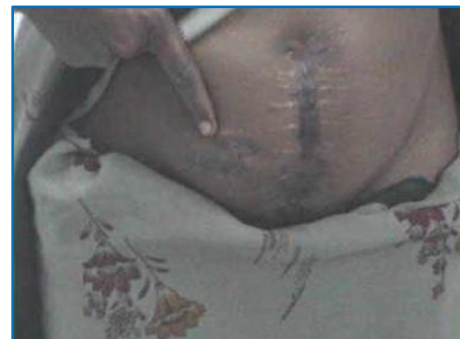**Fig. 5: Creation of submucosal tunnel**



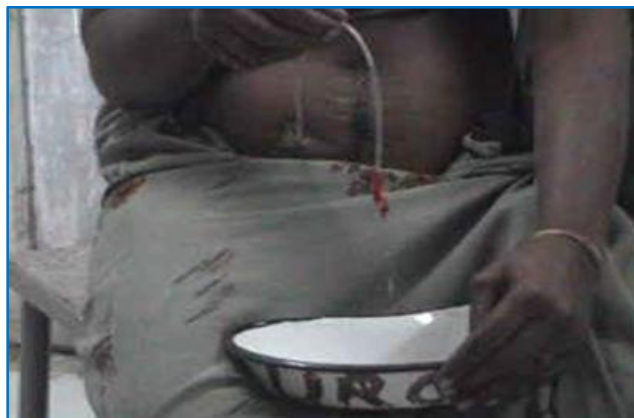**Fig. 6: Construction of stoma**



**Fig. 7: Completion of stoma  
And sub mucosal tunnel**



**Fig. 8: Patient showing  
appendicovesicostomy stoma**



**Fig. 9: Patient comfortably doing CIC**

## ORIGINAL ARTICLE

Age	No. of patients	Percentage
20-30	6	40%
30-40	2	13.33%
40-50	4	26.66%
>50	3	20%

**Table 1: Age wise distribution**

Sex	No. of patients	Percentage
Males	12	80%
Females	3	20%

**Table 2: Sex wise distribution**

Indication	No. of patients	Percentage
Failed urethra plasty	12	80%
Obstructed labour injury complex	3	20%

**Table 3: Indication for the procedure done**

Complication	No. of cases	Percentage
Subcutaneous wound infection	4	26.66%
Stomal stenosis	3	20%
Difficulty in catheterization	3	20%
Occasional cystitis	15	100%

**Table 4: Complications**

### REFERENCES:

- Mingin GC, Baskin LS (2003). Surgical management of the neurogenic bladder and bowel. *Int Braz J Urol* 29(1): 53-61. Doi: 10.1590/s1677- 55382003000100012. PMID 15745470.
- Farrugia MK, Malone PS. Educational article: The Mitrofanoff procedure. *J Pediatr Urol*. 2010 Aug; 6(4): 330-7. Doi: 10.1016/j.jpuro. 2010.01.015. Epub 2010 Feb 25.
- Merenda LA, Duffy T, Betz RR, Mulcahey MJ, Dean G, Pontari M (2007). Outcomes of Urinary Diversion in Children with spinal cord injuries. *J Spinal Cord Med*. 30 Suppl 1 (Suppl 1): S41-7 PMC 2031994. PMID 17874686.
- Thomas JC, Dietrich MS, Trusler L, De Marco RT, Pope JC 4<sup>th</sup>, Brock JW 3<sup>rd</sup>, Adams MC. Continent catheterizable channels and the timing of their complications. *J Urol*. 2006 Oct; 176 Oct; 176 (4Pt 2): 1816-20; discussion 1820.
- Suzer O, Vates TS, Freedman AL, Smith CA, Gonzalez R. Results of the Mitrofanoff procedure in urinary tract reconstruction; *Br J Urol*. 1997 Feb; 79(2): 279-82.
- Fishwick JE, Gough DC, O' Flynn KJ. The Mitrofanoff procedure: does it last? *BJU Int*. 2000; 85(4): 496-7.
- Liard A, Sequier- Lipszyc E, Mathiot A, Mitrofanoff P. The Mitrofanoff procedure: 20 years later; *J Urol*. 2001 Jun; 165(6 Pt. 2): 2394- 8.

## ORIGINAL ARTICLE

---

8. Clark T, Pope JC 4<sup>th</sup>, Adams MC, Wells N, Brock JW 3<sup>rd</sup>. Factors that influence outcomes of the Mitrofanoff and Malone ante grade continence enema reconstructive procedures in children; J Urol 2002 Oct ; 168 (4 Pt. 1): 1537-40; discussion 1540.

**AUTHORS:**

1. Immadi Chandrasekhar
2. A. V. Mohana Rao

**PARTICULARS OF CONTRIBUTORS:**

1. Assistant Professor, Department of Urology, Andhra Medical College, Visakhapatnam.
2. Assistant Professor, Department of Urology, Andhra Medical College, Visakhapatnam.

**FINANCIAL OR OTHER**

**COMPETING INTERESTS:** None

**NAME ADDRESS EMAIL ID OF THE CORRESPONDING AUTHOR:**

Dr. Immadi Chandrasekhar,  
9-7-289, Sairamnagar Lane,  
Besides O-Optex Showroom,  
Gajuwaka, Visakhapatnam- 530026,  
Andhra Pradesh.  
E-mail: vanajasekhar@yahoo.com

Date of Submission: 04/04/2015.  
Date of Peer Review: 05/04/2015.  
Date of Acceptance: 22/04/2015.  
Date of Publishing: 28/04/2015.